

A 42-year-old Man with Posterior Thigh Pain

Wei-Ting Wu, Ke-Vin Chang*

Department of Physical Medicine and Rehabilitation, National Taiwan University Hospital and National Taiwan University College of Medicine, Taipei, Taiwan

SECTION 1 – QUIZ

Case

A 42-year-old male suffered from the right posterior thigh pain after playing baseball 1 week ago. His pain could not be relieved by nonsteroid anti-inflammatory drug and got worse when jogging. He came to our clinic where ecchymosis and local tenderness were noticed at his right proximal thigh. An ultrasound examination was, therefore, applied using a curvilinear transducer. The short-axis and long-axis views of the ultrasound images over the painful site are presented in Figure 1a and b, respectively. The short-axis ultrasound image over the contralateral asymptomatic site is provided in Figure 2.

WHAT IS YOUR DIAGNOSIS?

Declaration of patient consent

The authors certify that they have obtained all appropriate patient consent forms. In the form, the patient has given

his consent for his figures and other clinical information to be reported in the journal. The patient understands that his name and initials will not be published, and due efforts will be made to conceal his identity, but anonymity cannot be guaranteed.

Acknowledgment

We would like to thank Lan-Rong Chen for editing the figure.

Financial support and sponsorship

The current article is supported by the Ministry of Science and Technology (109-2314-B-002-114-MY3).

Conflicts of interest

Dr. Ke-Vin Chang, an editorial board member at *Journal of Medical Ultrasound*, had no role in the peer review process of or decision to publish this article. The other author declared no conflicts of interest in writing this paper.

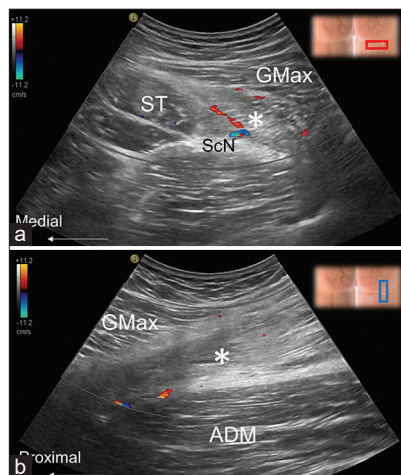


Figure 1: Ultrasound images over the proximal posterior thigh at the painful site at the short- (a) and long-axis (b) views. ST: Semitendinosus, GMax: Gluteus maximus, ADM: Adductor magnus; white asterisk, the lesion

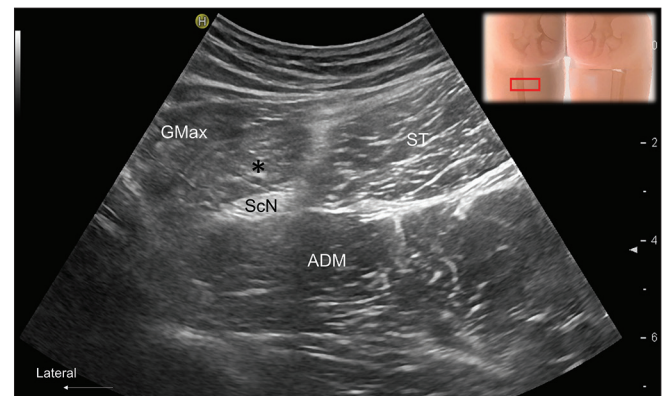


Figure 2: Ultrasound images over the proximal posterior thigh at the contra-lateral asymptomatic site at the short-axis view. ST: Semitendinosus, GMax: Gluteus maximus, ADM: Adductor magnus; black asterisk, long head of the biceps femoris

Address for correspondence:

Dr. Ke-Vin Chang,
Department of Physical Medicine and Rehabilitation, National Taiwan University Hospital, Bei-Hu Branch and National Taiwan University College of Medicine, No. 87 Neijiang St., Wanhua District, Taipei 108, Taiwan.
E-mail: kvchang011@gmail.com

Received: 20-10-2021 Accepted: 25-11-2021 Available Online: 19-05-2022

Access this article online

Quick Response Code:



Website:
<https://journals.lww.com/jmut>

DOI:
10.4103/jmu.jmu_193_21

This is an open access journal, and articles are distributed under the terms of the Creative Commons Attribution-NonCommercial-ShareAlike 4.0 License, which allows others to remix, tweak, and build upon the work non-commercially, as long as appropriate credit is given and the new creations are licensed under the identical terms.

For reprints contact: WKHLRPMedknow_reprints@wolterskluwer.com

How to cite this article: Wu WT, Chang KV. A 42-year-old man with posterior thigh pain. *J Med Ultrasound* 2023;31:169.